

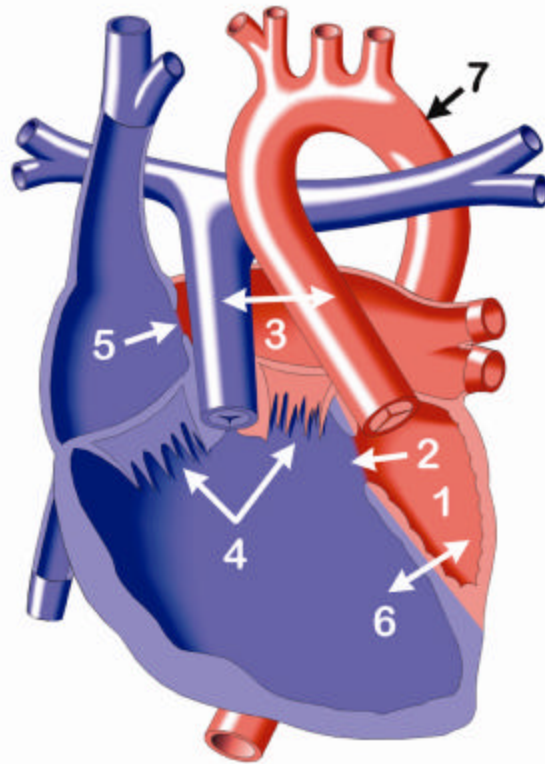
## Double Inlet Left Ventricle

In most forms of Double Inlet Left Ventricle, the positions of the great arteries (pulmonary artery and aorta) and the left and right ventricles are the reverse of the normal heart. The right ventricle is frequently small and both the mitral and tricuspid valve open into the enlarged left ventricle, which is on the right-hand side of the body. In addition, there are defects (openings) in both the atrial and ventricular septa (ASD and VSD).

Double Inlet Left Ventricle is one of the so-called Single Ventricle heart defects, as there is effectively only one pumping chamber in the heart.

In this defect, pulmonary blood flow (through the pulmonary artery to the lungs) is excessive. Affected infants usually cannot feed normally, and usually have difficulty gaining weight.

In some patients, there is mild obstruction to either systemic or pulmonary blood flow. Blood flow through the aorta to the body may become restricted if the size of the ventricular septal defect is too small, resulting in serious illness. (The only route of blood flow to the aorta is across the ventricular septal defect.)



### Above:

1. Rudimentary right ventricle
2. Ventricular septal defect (VSD)
3. Transposition of the great arteries
4. Double inlet left ventricle
5. Atrial septal defect (ASD)
6. Ventricular inversion (position of ventricles reversed from normal)
7. Left aortic arch

**Left:** Normal Heart

